



Variotime®

Tips & Tricks

## Tips & Tricks

### Two-step impression technique

Giving a hand to oral health.

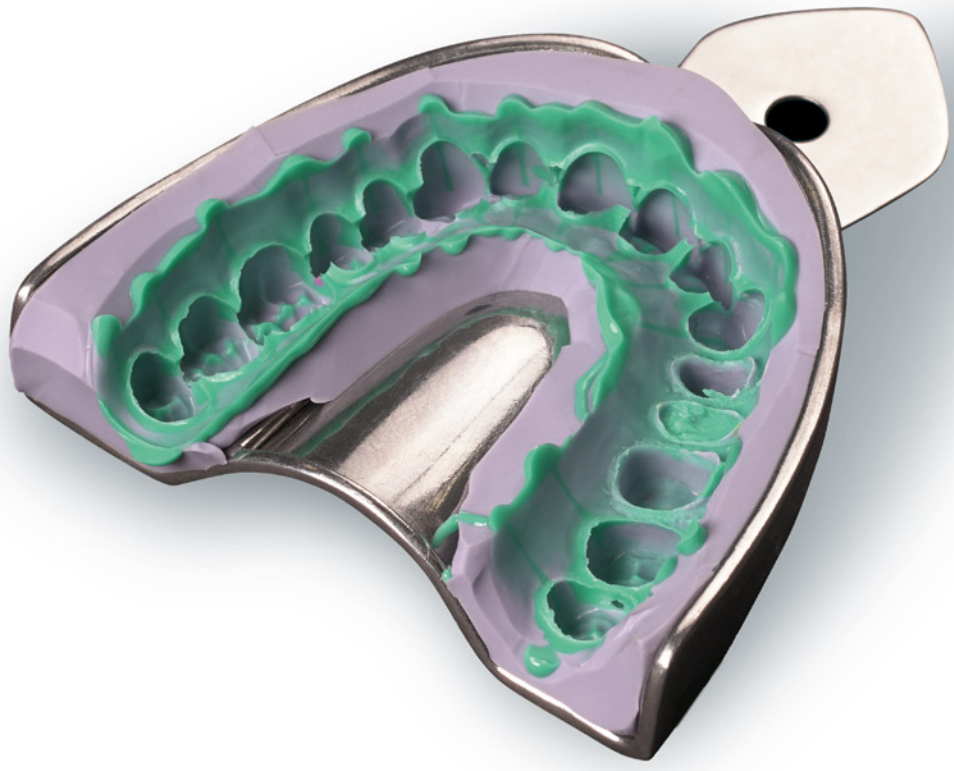


**KULZER**  
MITSUI CHEMICALS GROUP

# Content

<b>01</b>	Impression techniques	p. 06	<b>08</b>	Impression trays	p. 17
<b>02</b>	The Two-step impression	p. 07	<b>09</b>	Tray size	p. 18
<b>03</b>	Soft tissue management	p. 09	<b>10</b>	Damming and blocking out impression trays	p. 20
<b>04</b>	Retraction cords	p. 10	<b>11</b>	Tray adhesive	p. 22
<b>05</b>	Retraction cord techniques	p. 12	<b>12</b>	Mixing of A-silicones	p. 23
<b>06</b>	Vasoconstrictors and astringents	p. 14	<b>13</b>	Dosing of kneadable C-silicones	p. 24
<b>07</b>	Retraction pastes and gels	p. 16	<b>14</b>	Mixing of kneadable C-silicones	p. 26

<b>15</b>	Dosing of high-, medium- and low-viscosity C-silicones	p. 28	<b>22</b>	Assessment of the impression	p. 40
<b>16</b>	Mixing of high-, medium- and low-viscosity C-silicones	p. 29	<b>23</b>	Cleaning and disinfecting the impression	p. 41
<b>17</b>	Initial impression	p. 30	<b>24</b>	Storage and transport of the impression	p. 42
<b>18</b>	Trimming of the initial impression	p. 32	<b>25</b>	Opposing arch impression, bite registration and provisional	p. 43
<b>19</b>	Corrective impression	p. 36			
<b>20</b>	Working time and intraoral setting time	p. 38			
<b>21</b>	Removal of the impression	p. 39			



# Introduction

The precision impression is one of the most important prerequisites for perfectly fitting and long-lasting dental restorations.

The impression needs to accurately capture finest details to enable the fabrication of high-quality dental restorations. Thereby not only the quality of impression materials and the correct execution of impression taking play an important role, but also the soft tissue management and the handling of the materials in general.

Aim of Kulzer is not only to supply dentists and dental technicians with reliable materials but also to be a competent partner for dental questions. Hence, based on the extensive experience and cooperation with dental professionals a series of tips and tricks booklets around the topic of precision impression taking has been created.

The present tips and tricks guide deals with the Two-step impression technique in particular as well as the handling of impression materials and aids in general, and comprises practical advice on the impression taking procedure.



Dr. med. dent. Andrea Leyer  
Global Scientific Affairs Manager Disease Management  
and Pain Control, Indirect Restorations  
Hanau (Germany)



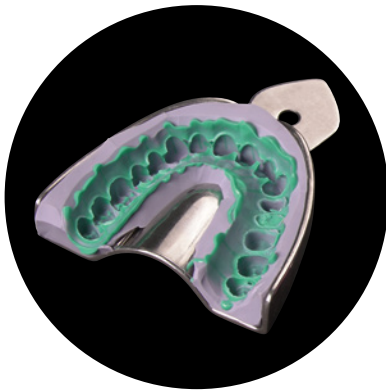
# 01

## Impression techniques

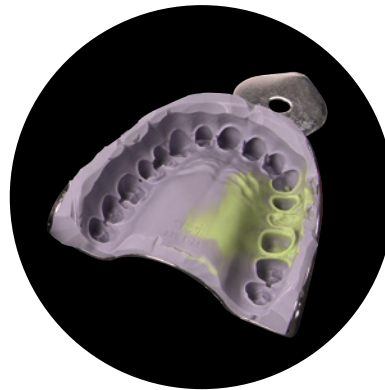Even in the age of digitalization the conventional precision impression belongs to the standard repertoire in the dental office. Mainly the following three techniques are used: The Two-step technique, the One-step technique and the Monophase technique (table 1, fig. 1).

	Two-step technique	One-step technique	Monophase technique
<b>Inlay/Onlay</b>		•	•
<b>Single crown</b>	•	•	•
<b>Bridge</b>	•	•	•
<b>Transfer-/implant impression</b>		•	•

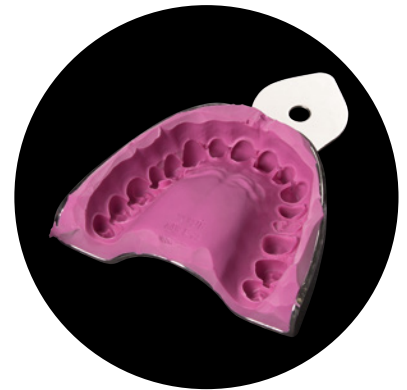Table 1: Overview of impression techniques and their possible areas of application.



a Two-step impression



b One-step impression



c Monophase impression

# 02

## The Two-step impression

In two consecutive steps (two stages) the impression is taken with two different viscosities of the silicone impression materials (two phases).

First step: Initial impression with a metal stock tray and a kneadable or high viscosity impression material (fig. 2). The initial impression is cut out to achieve a kind of “custom tray”.

Second step: Correction impression with a light body material (fig. 3).

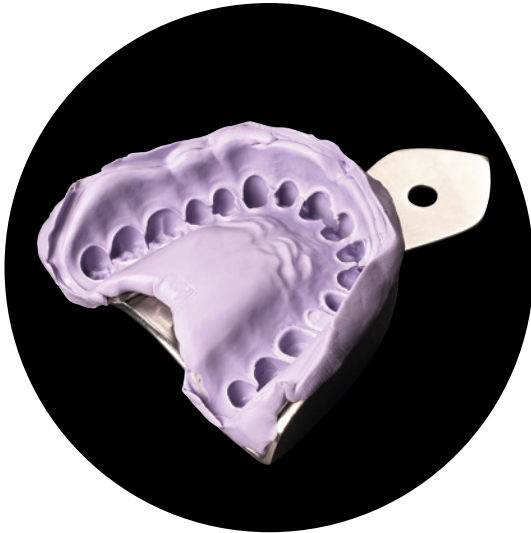


Fig. 2: Initial impression with Variotime Heavy Tray.

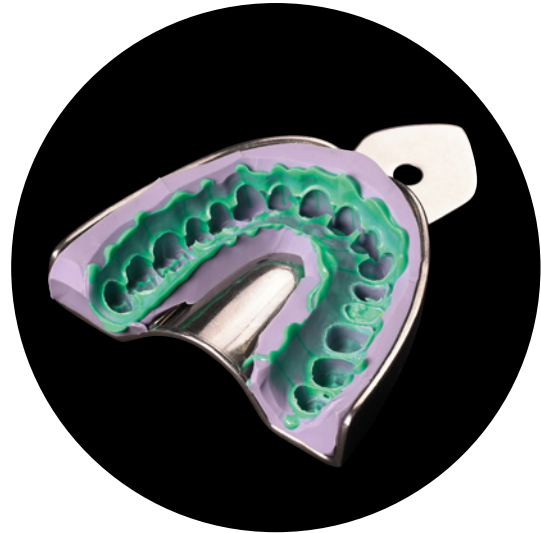

Fig. 3: Correction impression with Variotime Extra Light Flow.

With the Two-step impression technique (two stages, two phases) significantly higher hydraulic pressure can be achieved than with the One-step technique (one stage, two phases) or the Monophase impression technique (one stage, one phase), to reliably push the material in hard-to-reach areas, such as the sulcus. The Two-step impression technique thus is particularly recommended to capture subgingival preparation margins.

The Two-step impression is carried out with A- or C-silicone precision impression materials (fig. 4 & 5). Polyether are not suitable for this kind of impression technique.



**Hint:** A- and C-silicones should not be combined in the same impression, as they are two different types of silicones that do not achieve sufficient adhesion between each other.

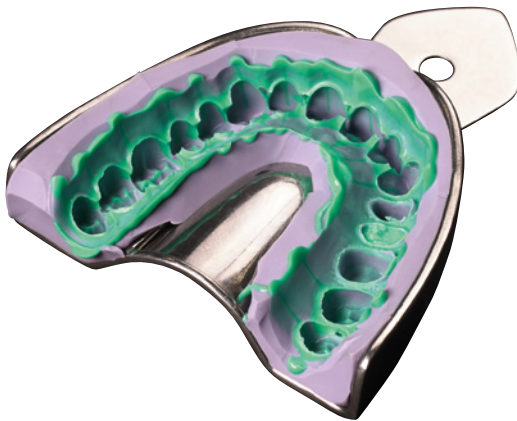


Fig. 4: Two-step impression with A-silicone (Variotime Heavy Tray & Variotime Extra Light Flow).

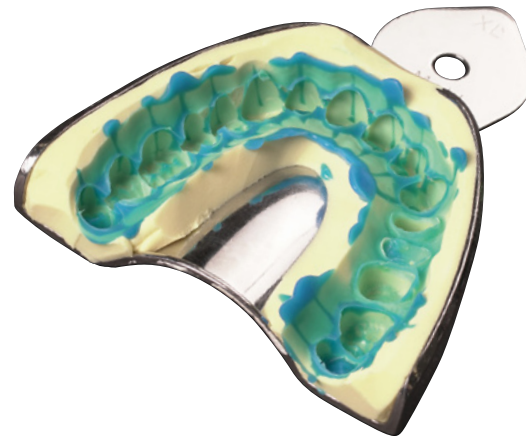


Fig. 5: Two-step impression with C-silicone (Optosil Comfort Putty & Xantopren L Blue).



## 03

## Soft tissue management

The marginal quality and thus the long-term success of a fixed restoration is significantly influenced by the reproduction of the preparation margin in the impression. Even though modern impression materials have a high degree of hydrophilicity and flowability, adequate isolation and clear depiction of the preparation margin, especially when subgingivally located, are essential (fig. 6 & 7). To enable the inflow of the impression material into the sulcus, the gingival tissue needs to be temporarily retracted and fluids such as blood or sulcus fluid have to be kept away.

In principle, mechanical, chemical and surgical methods are available for the displacement of the gingiva. The surgical procedure, i.e. the gingivectomy, is an irreversible intervention, and thus not suitable for a temporary retraction of the gingival tissue.

As mechanical aids for the temporary sulcus opening retraction cords, gels, pastes and special silicones are available. As chemical components for hemostasis, astringents and vasoconstrictors are in use. The most common method seems to be the combined chemo-mechanical technique. Besides the clinical situation, soft tissue management especially depends on the individual preference of the clinician.

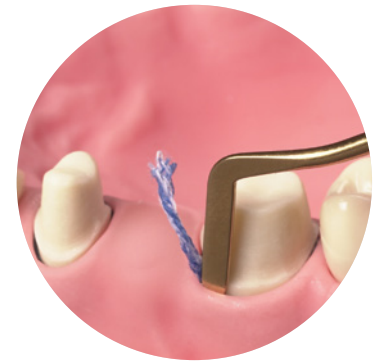
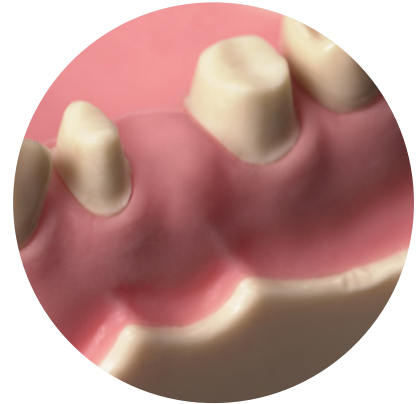

Fig. 6 & 7: Initial situation without retraction cord in place (above). In comparison, the depiction of the preparation margin with a retraction cord (below).



**Tip:** When having a hard to control bleeding, it is recommended to take the impression in a separate appointment at a later stage (about 8–10 days later). The follow-up appointment should not be too early as the granulation tissue during the healing phase easily tends to bleed.

# 04

## Retraction cords

Retraction cords are usually made of cotton, as cotton is well absorbing. Retraction cords are available in several diameters and various types, i.e. twisted, braided or woven. Furthermore, a distinction is made between impregnated and non-impregnated cords. Impregnated cords are already pretreated by the manufacturer with a chemical agent for hemostasis. As the active agent in the impregnated cord is present in the dried form, sufficient sulcus liquid needs to be present for its elution.

Mechanical retraction with non-impregnated cords alone seems to be less suitable for a successful tissue management as the cord removal can cause a hyperemic response and an increase of the sulcus fluid flow rate. Thus, when using a non-impregnated cord it is suggested to soak it with a suitable retraction solution (fig. 8 & 9). Cords that are already impregnated by the manufacturer must not be additionally soaked with a retraction solution due to possible interactions.



**Tip:** After having soaked the cords, slightly dry them prior to the application in the mouth (fig. 10).




Fig. 8 & 9: Impregnation of a non-impregnated retraction cord.

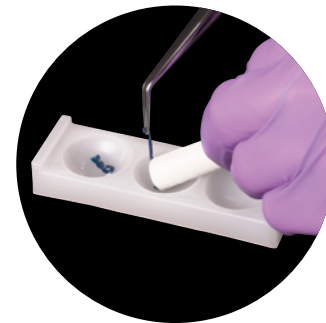


Fig. 10: Slightly dry the cord after removal from the retraction solution.



**Hint:** Mixing of different agents should be avoided due to possible unwanted effects. For example, mixing of epinephrine with ferric sulfate preparations leads to the appearance of a difficult to remove blue/black precipitate (fig. 11).



Fig. 11: In the left hollow: non-impregnated cord, soaked in ferric sulfate (no discoloration). In the central hollow: cord pre-impregnated with epinephrine, additionally soaked in ferric sulfate (blue/black discoloration due to the interaction).

# 05

## Retraction cord techniques

Basically there are two different retraction cord techniques: the single cord technique and the double cord technique (fig. 12).

**Single cord technique:** one single retraction cord is placed into the gingival sulcus (fig. 13 & 14). After the appropriate length of stay (always follow the instructions of use) the cord is removed immediately prior to impression taking. The single cord technique is recommended when having a shallow sulcus or only a few prepared teeth.

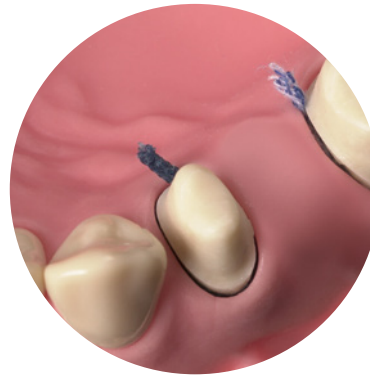
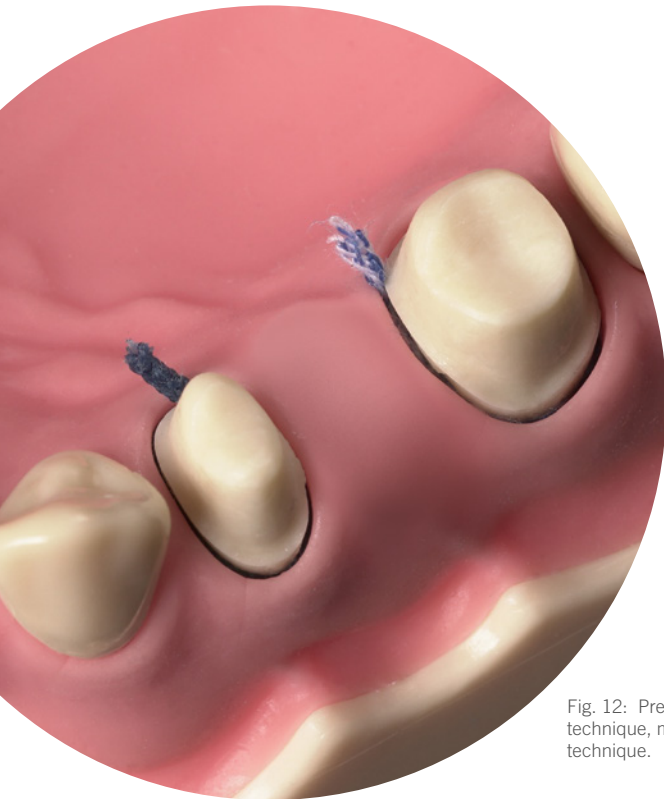


Fig. 12: Premolar with single cord technique, molar with double cord technique.

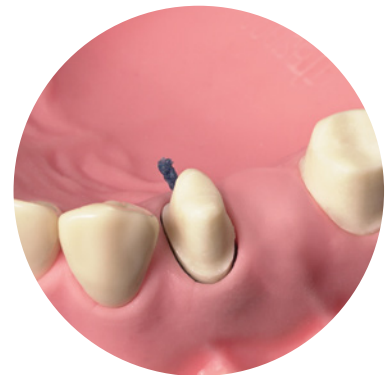

Fig. 13 & 14: Placement of the impregnated retraction cord for the single cord technique (above). Clearly visible preparation margin at the premolar after cord placement (below).

**Double cord technology:** First, a thinner cord is introduced into the sulcus slightly below the preparation margin; afterwards a second thicker cord is placed on top (fig. 15 & 16). Only the second cord is removed immediately prior to impression taking. That technique is especially recommended when having a deep sulcus or multiple prepared teeth.

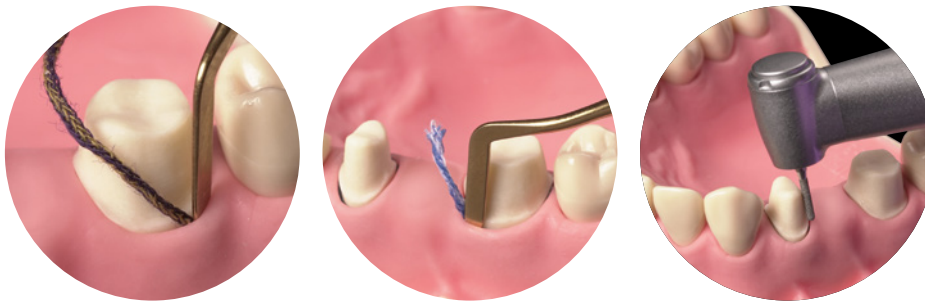


Fig. 15 & 16: Combination of a thinner first cord (left) with a second thicker cord for the double cord technique (right).

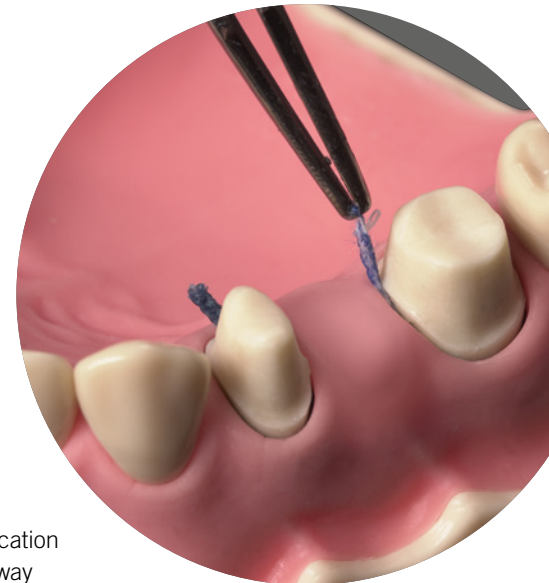
Fig. 17: Finishing of the preparation margin with a retraction cord in place.

The retraction cord should be sufficiently long without overlapping in the sulcus. If the cord is too short, the tissue between the cord endings will not be sufficiently displaced. For the cord removal the cord should not be completely dry as it can injure the tissue and induce bleeding once again. Immediately after successful impression taking, remaining cords have to be removed from the sulcus (double cord technique!). Any cords or residues of cords left behind in the sulcular area can cause massive inflammations.



**Tip:** Finishing of the preparation margin after placement of the first retraction cord in order to protect the marginal gingiva from a potential injury by rotating instruments (fig. 17).

Fig. 18: A protruding cord end enables easy grasping with tweezers for the cord removal.



**Tip:** Ideally, a small part of the cord protrudes from the sulcus to facilitate grasping of the cord with the tweezers for a quick removal prior to the application of impression material (fig. 18). Positioning of the protruding cord end in a way that it is easily accessible by the person that is supposed to grasp it.

# 06

## Vasoconstrictors and astringents

As chemical components for local hemostasis during soft tissue management, vasoconstrictors or astringents are used. Usually they are combined with a mechanical component: chemo-mechanical retraction (fig. 19 & 20).




Fig. 19 & 20: Soaking of a non-impregnated retraction cord for chemo-mechanical retraction.

Vasosonstrictors, such as adrenaline (epinephrine), have a vasoconstrictive effect. However, it must be kept in mind that they also have a systemic effect and can influence the cardiovascular system.

The effect of astringent agents (e.g. ferrous sulfate, aluminum chloride) is based on their ability for precipitation of proteins. Ferrous salt compounds: By local precipitation of proteins in the blood, ferrous sulfate causes obstruction of the blood vessels. Aluminum salt compounds: The precipitation of proteins results in a slight tissue shrinkage and thus in the constriction of the capillary blood vessels in it.



**Hint:** Due to the systemic effect of epinephrine care should be taken with epinephrine-soaked retraction cords in risk patients, e.g. patients with cardiovascular diseases. Furthermore, the risk of overdosing due to cumulative effects of epinephrine containing retractions cords and epinephrine containing local anesthetics needs to be considered (dependent on the number of cords, duration of application, amount of local anesthetic injected, etc.) Alternatively, astringent agents that have no systemic effect can be used.



**Hint:** Astringents have a very low pH-value, so that a prolonged application time in the sulcus can cause chemical burns of the soft tissue. Hence, the recommended application times in the respective instructions of use have to be strictly followed.




Fig. 21: Placement of an impregnated cord on freshly mixed impression material in order to test the compatibility.



Fig. 22: Absence of an unpolymerized layer (smear layer) shows compatibility of the used materials.

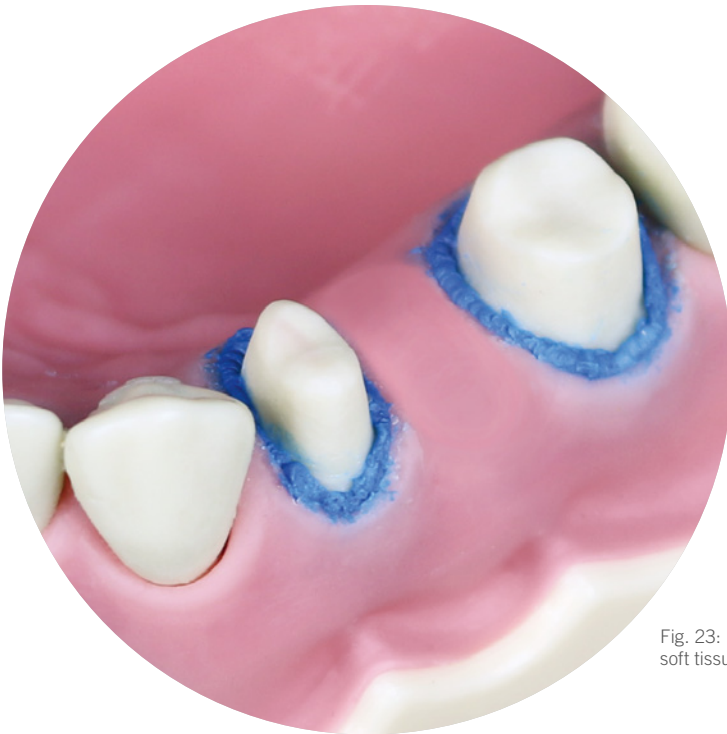


**Tip:** Astringents can have an impact on the setting reaction of A-silicones. In case of unclarity (e.g. when changing the impression material or retraction aid) the compatibility should be tested beforehand (fig. 21). For this purpose, a piece of the respective cord is placed on freshly mixed impression material. Once the impression material is set, the cord is removed and the contact area of the two materials is inspected: absence of an unpolymerized layer (smear layer) shows compatibility of the two materials (fig. 22).

# 07

## Retraction pastes and gels

As an alternative to retraction cords, various pastes and gels for soft tissue management are available. Retraction pastes and gels usually contain an astringent component (often aluminum chloride 15%) which is responsible for the hemostatic effect, and a component for the tissue displacement (often kaolin, that absorbs sulcus fluid and expands). Usually the pastes are introduced into the sulcus with a blunt cannula and rinsed out after a certain application time. It very much depends on the clinical situation if such a procedure is suitable to replace the retraction cord.



**Hint:** Prior to the first usage it is recommended to check the compatibility of retraction pastes or gels with the impression material used in the dental practice.

Fig. 23: Use of a retraction paste for soft tissue management.



## 08

## Impression trays

The impression tray is, so to say, the “backbone” of the impression and thus plays a very important role concerning the quality of the impression. An adequate impression tray should be rigid, i.e. torsion-resistant. For the Two-step impression technique metal trays should be preferred, as plastic trays might not be sufficiently torsion-resistant. Additionally, the tray for the Two-step technique should have retentions, i.e. a retention rim (Rim-Lock-tray) or perforations.



Fig. 24: Trays suggested for highly viscous impression materials (heavy tray): e.g. individual tray, Border-Lock tray, Rim-Lock tray, non-perforated Ehrlicke tray.



Fig. 25: Trays suggested for kneadable materials (putty): e.g. Aesculap tray, Rim-Lock tray, perforated Ehrlicke tray, unperforated Ehrlicke tray.



**Hint:** When using a highly viscous impression material (heavy tray) for the initial impression, an unperforated tray should be chosen (fig. 24).



**Hint:** When using a kneadable impression material (putty) for the initial impression, perforated as well as non-perforated impression trays can be used (fig. 25).

# 09

## Tray size

The tray size depends on the clinical situation. Especially when having large undercuts of the jaw or strong divergence respectively convergence of the remaining teeth, particular attention must be paid to the size of the tray. Also in the area of the largest undercut (later the section that undergoes the highest compression) sufficient distance between tray wall and tooth equator needs to be available (fig. 26 & 27), in order to ensure an easy mouth removal without permanent deformation of the impression material. Too low material thickness results in such a high compression of the impression material that it can not completely recover.



**Tip:** Rule of thumb for sufficient material thickness: Distance between tooth equator and tray wall needs to be at least twice as big as the extent of the undercut (fig. 26). That goes along with a later compression of the impression material by only one third (fig. 27) which allows a complete recovery of the impression material.

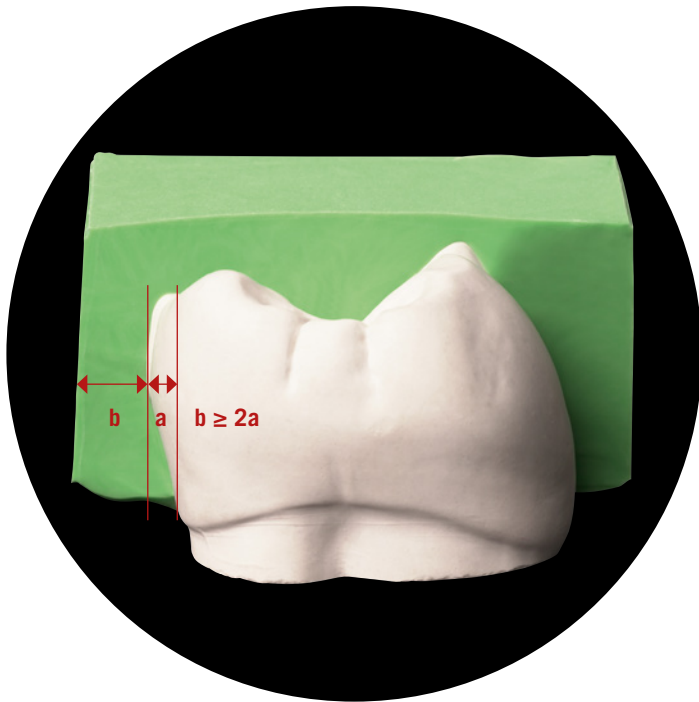


Fig. 26: The distance between tooth equator and tray wall (b) should be at least twice as big as the extent of the undercut (a).

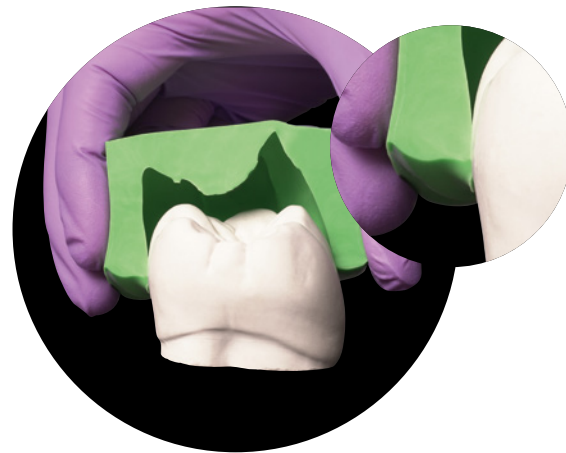


Fig. 27: Highest compression in the area of the tooth equator.




**Hint:** For maxillary trays the distance in the buccal area, for mandibular trays the distance in the lingual area often is too small (fig. 28). At the first glance, the tray seems to be well fitting but indeed the jaw can have large undercuts. Thus, in the upper jaw a bigger tray size is to be preferred as the undercuts are buccally located. In the lower jaw a smaller tray size might be more advantageous as the undercuts are lingually located. However, there should be a minimal distance of at least 3 mm between tray wall and jaw (fig. 29).



Fig. 28: Buccally the space would be sufficient, but lingually the tray sits far too close.

Fig. 29: Sufficient distance to the tray wall on both sides.



# 10

## Damming and blocking out impression trays

Damming can become necessary in serial trays without boundary in the dorsal area (e.g. Rim-Lock or Ehrlicke tray). Dorsal damming of the impression tray inhibits leakage of the impression material from the impression tray in the distal region. On the one hand, it can be prevented that surplus impression material flows into the patient's throat and induces a gag reflex. On the other hand, flow defects in the dorsal area can be avoided: in trays without dorsal damming the impression material can flow off distally, so that the terminal teeth are not fully captured by the impression material (fig. 30).

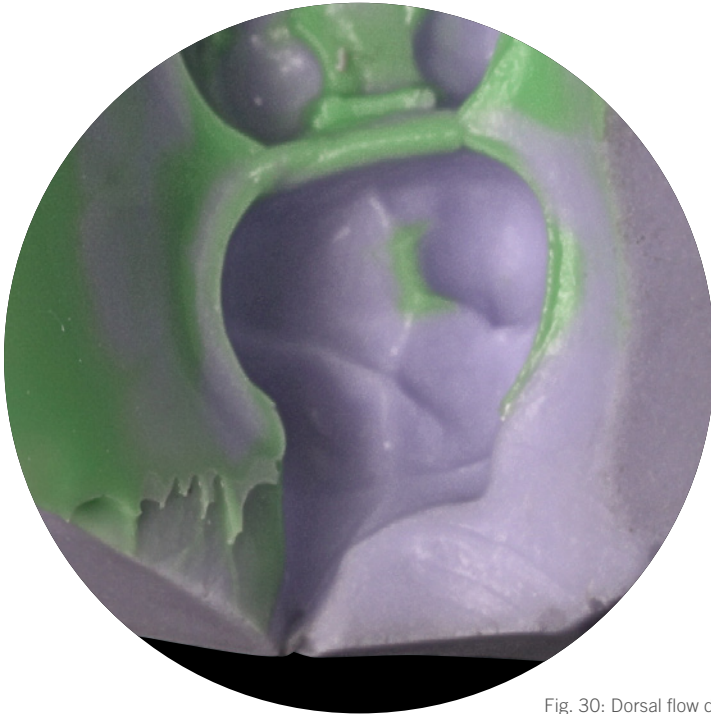


Fig. 30: Dorsal flow defect.

For blocking out in the dorsal area, tray plastics or thermoplastic materials can be used. Blocking out in the palatal area is done with kneadable impression materials.

This is often necessary for prefabricated maxillary trays, when the palate of the patient is high and narrow. Otherwise, without a blocked-out palate, the impression material flows off into that “cavity”, that does not offer any resistance. Thus, no adequate hydraulic pressure can be achieved, which is necessary to push the impression material into hard-to-reach areas of the jaw. The consequence are deep grooves that reach from the palatal tooth necks of the posterior teeth to the palate.



**Hint:** The prepared tray should be tried on in the patient's mouth to avoid that the blocked-out area is too high. The teeth need to be completely captured by the impression tray despite the blocked-out area.

# 11

## Tray adhesive

During the removal of the tray from the mouth the impression is subjected to enormous stresses, especially when the jaw exhibits strong undercuts. Optimal adhesion can only be achieved by using an adhesive that is suitable for the respective impression material, i.e. each impression material (e.g. alginate, silicone, polyether) needs its special adhesive. To avoid stains on the practice furniture, the worktop can be covered with cellulose cloth that is fixed with adhesive crepe tape.

Ideally, the adhesive is applied in a thin layer shortly before impression taking (fig. 31 & 32), whereby it is necessary to observe the drying time declared by the manufacturer (fig. 33). The adhesive can only achieve optimal adhesion when the solvent is completely evaporated.



**Hint:** Each impression material (e.g. alginate, silicone, polyether) needs its special adhesive. Optimal adhesion can only be achieved by using an adhesive that is suitable for the respective impression material.



**Tip:** Residues of the silicone tray adhesive Universal Adhesive (Kulzer) can be removed from the tray with ethyl alcohol.

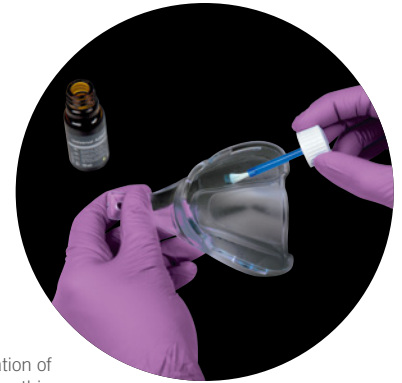

Fig. 31: Application of tray adhesive in a thin layer with an accompanying brush.

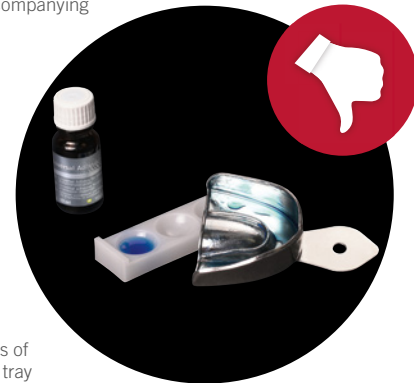


Fig. 32: Puddles of adhesive in the tray must be avoided.

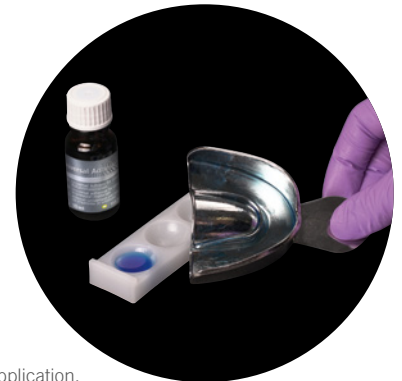


Fig. 33: After application, the adhesive is let to dry according to the instructions for use.

# 12

## Mixing of A-silicones

A-silicones are available in cartridges for automixing or in tubes and tubs for manual mixing. During manual mixing, the quality is dependent on the individual skills of the user. Manual mixing bears the risk of inhomogenous mixing quality and dosage errors (under- or overdosing of components). Automixing offers several advantages over manual mixing, such as standardized mixing, homogenous mixing quality, quick and hygienic processing as well as precise dosing and material saving.

When using an automix system (fig. 34) the initial 2–3 cm of the material have to be discarded prior to the first use, to adjust the filling levels of the two material components (fig. 35).

Base- and catalyst paste of the A-silicones for manual mixing have the same viscosity and are mixed in a 1:1 ratio. To avoid contamination, the tubs should be sealed carefully immediately after usage. In general, care should be taken not to interchange the respective lids or spoons (fig. 36 & 37).



Fig. 34: Variotime Heavy Tray in the automatic mixing device Dynamix speed 2.

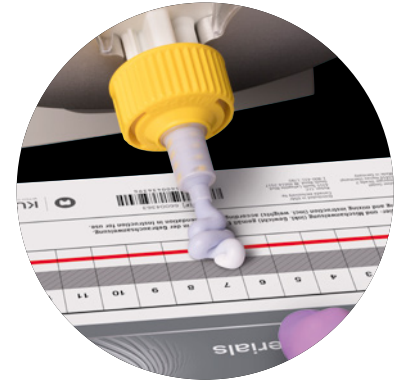

Fig. 35: Discarding of the initial 2–3 cm to adjust the filling levels of the two material components.



Fig. 36 & 37: Lids and spoons are colour matched to the respective material in order to avoid confusion.



**Hint:** As latex can affect the setting behavior of A-silicones, vinyl or nitrile gloves can be worn for mixing.

# 13

## Dosing of kneadable C-silicones

Kneadable condensation curing silicones (C-silicones) are delivered in tubs together with spoons for the withdrawal. Ideally, the excess material is removed after the withdrawal in two portions, so that the spoon is filled to the rim (fig. 39–42). The amount of material needed for the impression has to be estimated by the size of the jaw respectively the impression tray.



**Hint:** The mixing pad (item number 66004363), which can be purchased separately, and the spoon can be used for application. The correct mixture can only be guaranteed, if the exact weights and volumes listed in the instructions for use are used.



Fig. 38: Always use the scales to ensure exact dosage.

The measured amount of putty material is pressed flat with the ball of the thumb on the mixing pad. With the open side of the measuring spoon a circle is marked. The imprinted circle serves as a dosing aid for the application of the activator paste (fig. 43–46). One strand of activator paste is applied per spoon of putty material (e.g. 1 spoon putty material used = 1 strand of activator paste, or 4 spoons putty material used = 4 strands of activator paste) in the diameter of the circle (fig. 47–49).

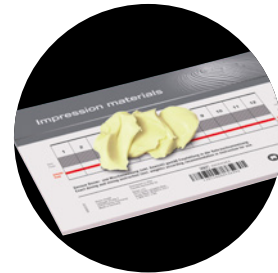





Fig. 39–41: Removal of the excess material in two portions in order to achieve a correct dosing (i.e. an evenly filled spoon).



Fig. 42: Removal of the excess material in one go should be avoided as the material can be pushed out from the spoon resulting in underdosing.



Fig. 43–46: The measured amount of material is pressed flat with the ball of the thumb. The measuring spoon is used to mark a circle as dosing aid for the activator paste.

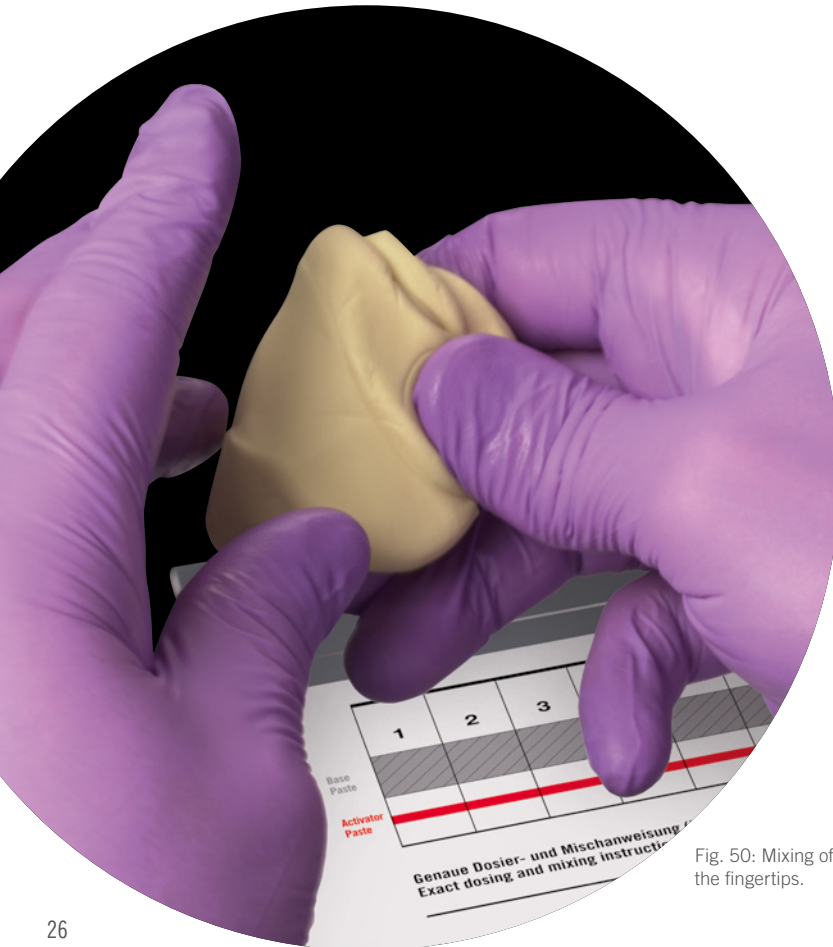


Fig. 47–49: Correctly dosed strands (left). In comparison, unevenly and too thin (middle) respectively too thick dispensed strands (right).

# 14

## Mixing of kneadable C-silicones

After correct dosing of silicone and activator paste, both are taken from the pad. The two components are mixed between the fingertips by folding (fig. 50) within the specified mixing time until the activator is evenly distributed in the silicone.



**Tip:** When kneading between the fingertips less heat develops than when kneading in the palm.

Fig. 50: Mixing of the silicone between the fingertips.

Even if the colour of the activator is no longer visible in the mixture before the end of the specified mixing time, mixing needs to be proceeded until the end. Disappearance of the activator colour is no clear sign for a completely homogenous mixture. Insufficiently mixed-in activator results in an “onion skin” structure of the set material. The impression then consists of multiple layers that can be easily separated (fig. 51), impairing the accuracy of the impression result.

At the end of the mixing time, the silicone mixture is rolled to a strand as broad as the palm (fig. 52) and is evenly distributed in the impression tray until the height of the rim (fig. 53 & 54). Surplus material is removed.

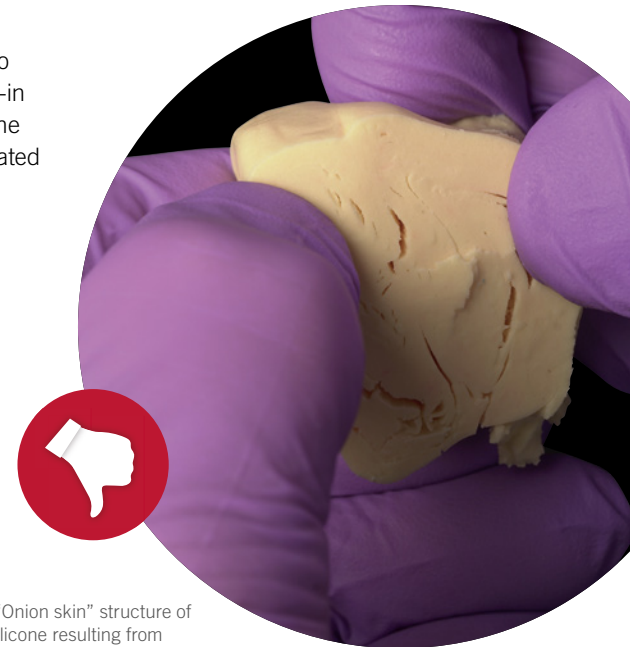

Fig. 51: “Onion skin” structure of the set silicone resulting from insufficiently mixed-in activator.

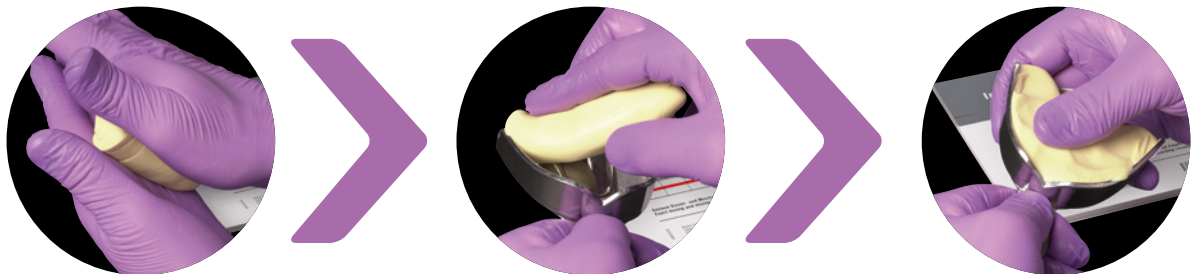


Fig. 52–54: For filling the impression tray, the material is rolled to a strand that is applied into the tray and evenly distributed.

# 15

## Dosing of high-, medium- and low-viscosity C-silicones

Some low-viscosity C-silicones are available in automix cartridges, otherwise high-, medium- and low-viscosity C-silicones are available in tubes for manual mixing. The separately available mixing pad can be used for application. These types of silicones in tubes are mixed with activator pastes that are applied in the respective strand length. Based on the number of graduations of the used silicone base material, the related number of graduations of the paste activator is applied on the mixing pad (fig. 55 & 56). Thereby an even strand thickness should be ensured (fig. 56). For details consult the instructions for use.



Fig. 55 & 56: Pre-dosing of base materials and paste activator.



**Hint:** The mixing pad (item number 66004363), which can be purchased separately, can be used for application. The correct mixture can only be guaranteed, if the exact weights and volumes listed in the instructions for use are used. Therefore, **always use the scales to ensure exact dosage.**

## 16

## Mixing of high-, medium- and low-viscosity C-silicones



Fig. 57–59: Premix with circling movements, take up the mixture with the spatula and spread it out widely.

Both components (base material and activator) are premixed on the mixing pad with circling movements of the spatula (fig. 57). Afterwards the mixture is taken up with the spatula (fig. 58) and spread out widely and thinly on the pad (fig. 59). That procedure is repeated until the activator is evenly distributed in the base material (silicone). Here too, the specified mixing time must be maintained. This also applies for small quantities that are supposedly quickly mixed. However, undercutting the mixing time can result in a non-visible inhomogenous mixing of the silicone that only becomes apparent in permanently soft areas of the finished impression. These areas are plastic deformable and unsuitable for the fabrication of an accurate model.

Filling of a syringe: For low-viscosity C-silicones, that shall be used for syringing the teeth in the mouth or that shall be applied into the initial impression, special delivery syringes are available. With quick pushing movements the material can be taken up from the mixing block (fig. 60).

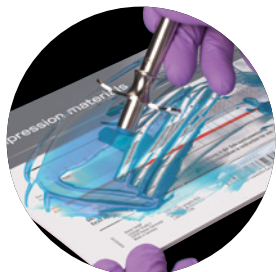


Fig. 60: Uptake of the material from the mixing pad by quick pushing movements with the syringe.

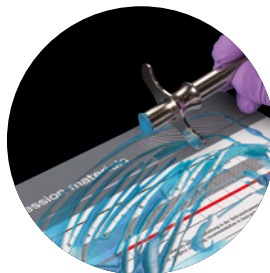


Fig. 61: Spreading out the impression material on the pad previously allows the clean filling of the syringe.



**Tip:** To avoid the inclusion of air bubbles during mixing, the material should not be stirred but spread out thinly and widely (fig. 59).



**Tip:** To avoid smudging the handle with impression material during syringe filling, spread out the impression material very thinly on the mixing pad (fig. 61).

# 17

## Initial impression

Mostly, a kneadable silicone is used for the initial impression. Alternatively a highly-viscous impression material (shore A hardness preferably in the range of 65–72) in combination with an unperforated impression tray can be used. The tray is filled approximately till the rim but not beyond (fig. 62 & 63). Too much material can hamper the impression taking process: the surplus material increases the resistance during insertion and is felt as unpleasant by the patient.



**Tip:** Advantage of automatic over manual mixing is the homogenous and void-free mixing quality as well as the possibility to exactly dose the required amount of material.

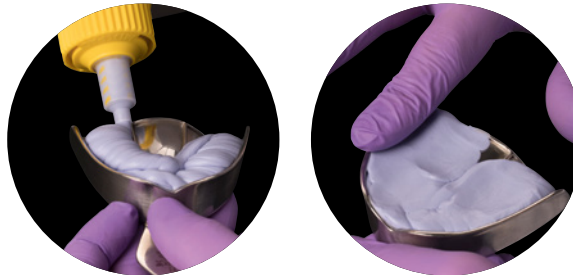


Fig. 62 & 63: The tray is filled until the rim and the surface is smoothed.

If present, extensive undercuts (e.g. suspended bridge) should be blocked out with an appropriate wax prior to impression taking. Remember to remove the wax afterwards.

For the insertion of the tray one corner of the mouth is kept away with the finger and the other side is displaced with the slightly inclined tray (fig. 64). Afterwards the tray is aligned straightly and pushed into position from the back to the front in order to prevent excess material from flowing into the patient's throat (fig. 65).



**Hint:** If a composite build-up filling was placed or a methacrylate-based provisional was fabricated in the same session, the smear layer needs to be removed with a cotton pellet soaked in alcohol prior to impression taking. Otherwise, the setting reaction of the impression material can be affected.

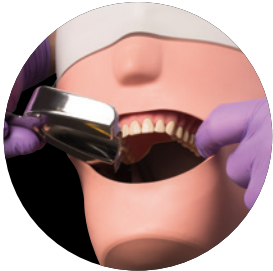

Fig. 64: One corner of the mouth is kept away with the finger, the other side is displaced with the impression tray.

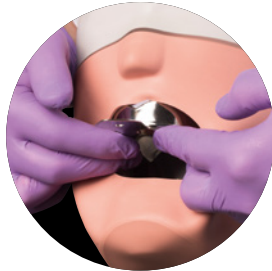

Fig. 65: Alignment of the tray so that the jaw is positioned centrally in the tray, then the tray is pushed into position from the back to the front.



**Hint:** The jaw should be positioned centrally in the tray to achieve an even layer thickness (at least 3 mm).



**Tip:** When the mouth is opened too wide, the ascending lower jaw branch can interfere. Thus, the mouth should not be opened to the maximum, but the lips should still be relaxed.

Once the material has set, the initial impression is removed from the mouth, cleaned under running water from blood and saliva and dried with the air syringe. Now the quality can be evaluated (fig. 66):

- All teeth of the jaw need to be entirely captured in the impression material and need to be completely located in the impression tray (material exceeding the rim will be cut away in the next step). Particular attention should be paid to the terminal teeth (exceptions could be teeth without antagonist contact or missing antagonist teeth).
- The jaw should be located centrally in the tray to ensure a uniform distance between jaw and tray wall (3mm minimum layer thickness).
- The tray should not be pushed against the occlusal/incisal edges, i.e. the tray bottom should not be visible in the impression. By direct pressure of the rigid tray on the teeth, the teeth can be pushed into the socket and thus get recorded in a physiologically incorrect position. Incisal/occlusal inaccuracies of the restoration can be the consequence.

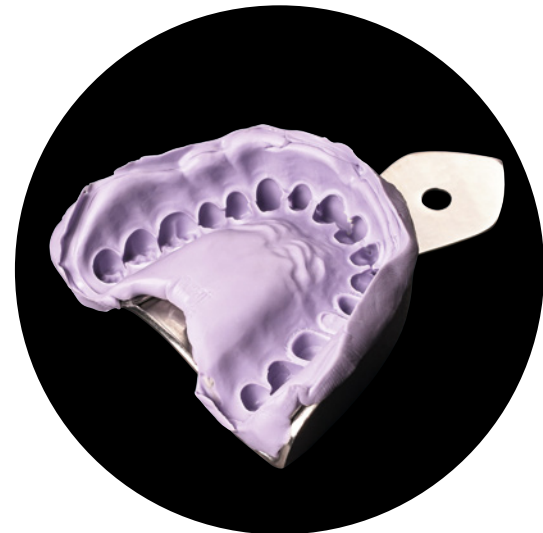


Fig. 66: Initial impression after removal.

# 18

## Trimming of the initial impression

If the initial impression is suitable for processing, it is trimmed with a sharp scalpel.

Various opinions exist on how to trim the impression, one of them will be exemplary displayed in the following:

Cut away material that is exceeding the rim of the impression tray (fig. 67), also in the dorsal area (fig. 68).



**Tip:** Scalpel blade number 11, for example, is very suitable for trimming the initial impression: the extended edge is broad enough to cut away the margins and its pointed tip allows to cut “escape channels”.

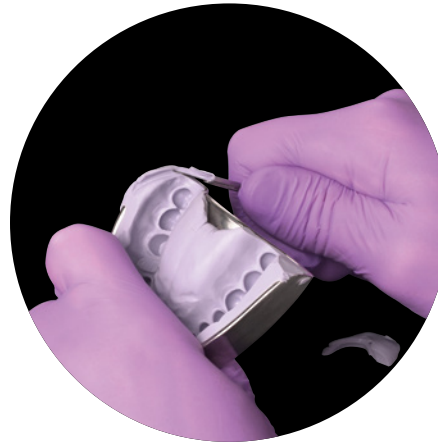
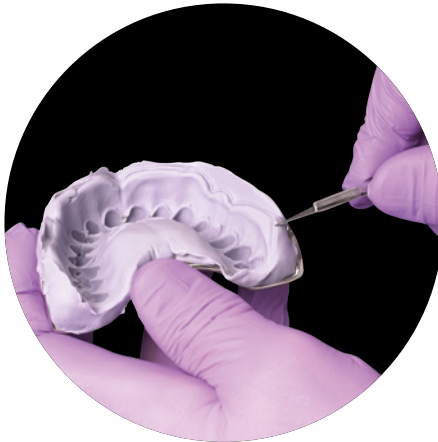
Fig. 67 & 68: Material exceeding the rim of the impression tray is cut away.



Cut the palate to a plane surface or cut it away completely (fig. 69).  
Break the lateral edges (fig. 70).

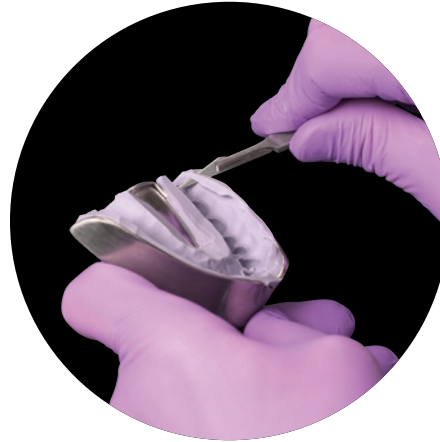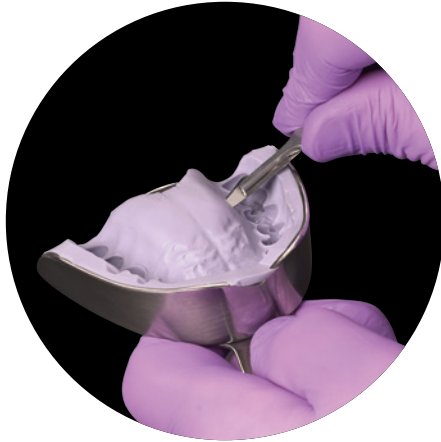


Fig. 69 & 70: Cut the palate to a plane surface or cut it away completely. Break the lateral edges.



Carefully cut away interdental areas and undercuts without damaging the incisal and occlusal surfaces (fig. 72). Only completely intact incisal and occlusal surfaces allow an exact and stable repositioning of the impression. The prepared teeth are not trimmed.

**Tip:** A locating groove in the impression material between the two central incisors facilitates a quick intraoral repositioning of the impression in the correct place (fig 71).

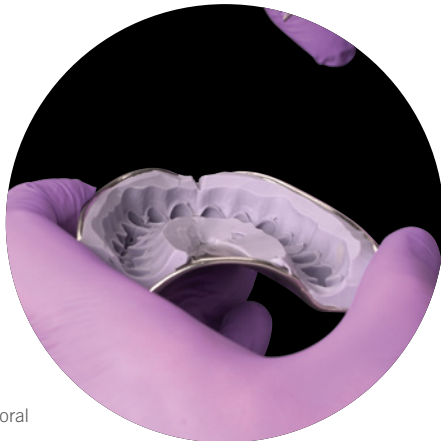


Fig. 71: A locating groove between the two central incisors facilitates the intraoral repositioning.

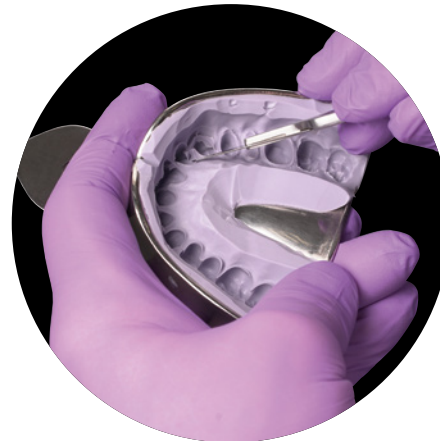


Fig. 72: Cut away interdental areas and undercuts.

Carve the “escape channels”. The channels are always created opposite each other (fig. 73 & 74).

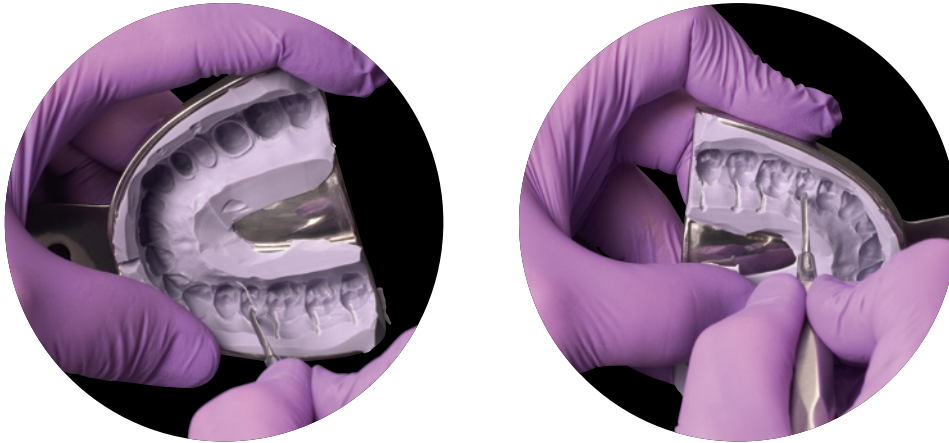


Fig. 73 & 74: Carving the escape channels for the wash material with the U-Cutter (Kentzler and Kaschner). The channels are always created opposite each other.

Various methods for cutting “escape channels” in the initial impression exist, e.g. usage of a scalpel. However, to achieve uniform channels with a scalpel requires quite some experience and is relatively time-consuming. In any case the grooves should be sufficiently large and uniform in width and depth. If the escape channels are too small, the impression material can not flow off adequately and too high dynamic pressure builds up.

At the unprepared teeth the escape channels should reach until the tooth equator. At the prepared teeth the channels can violate the preparation margin but do not necessarily have to, i.e. optionally (depending on the approach) the escape channels terminate just before the preparation margin.



**Tip:** Very suitable for carving the escape channels is the impression cutting tool U-Cutter from the company Kentzler and Kaschner Dental GmbH (fig. 73 & 74).

Finally, the impression is thoroughly cleaned with the air syringe. No material residues or loose material flags should be left behind in the initial impression. Subsequently the impression is repeatedly repositioned in the mouth. The impression needs to be quickly and clearly repositionable, during removal the material is not allowed to tear. Afterwards the impression is thoroughly cleaned with water and dried.



**Hint:** Insufficient/incorrect trimming of the initial impression results in a displacement of the tray material in the second step of the Two-step technique. After removal from the mouth, the tray material then “springs back” and the lumina are too small.



**Tip:** Loose flags of the impression material can be easily detected with the air syringe and need to be removed.

# 19

## Corrective impression

The retraction cords are not removed until immediately before the actual corrective impression. If necessary, the sulcus needs to be rinsed in order to remove residues of retraction solutions that could impair the setting reaction of the silicone.

With the dispensing gun or application syringe a thin layer of correction material is applied into the lumina of the unprepared teeth in the initial impression (fig. 75). If the escape channels are uniform and not too broad, it is sufficient that the wash material covers the lumina of the posterior teeth and fills about one third of the front teeth. Application of too much impression material results in a too thick layer of the wash material and may induce inaccuracy of fit in the restoration. For syringing around the prepared teeth an intraoral tip is placed on the mixing tip.



**Tip:** The wash material is applied into the initial impression prior to syringing the prepared teeth. The setting reaction of the material proceeds more slowly outside the mouth than in the warm oral cavity.

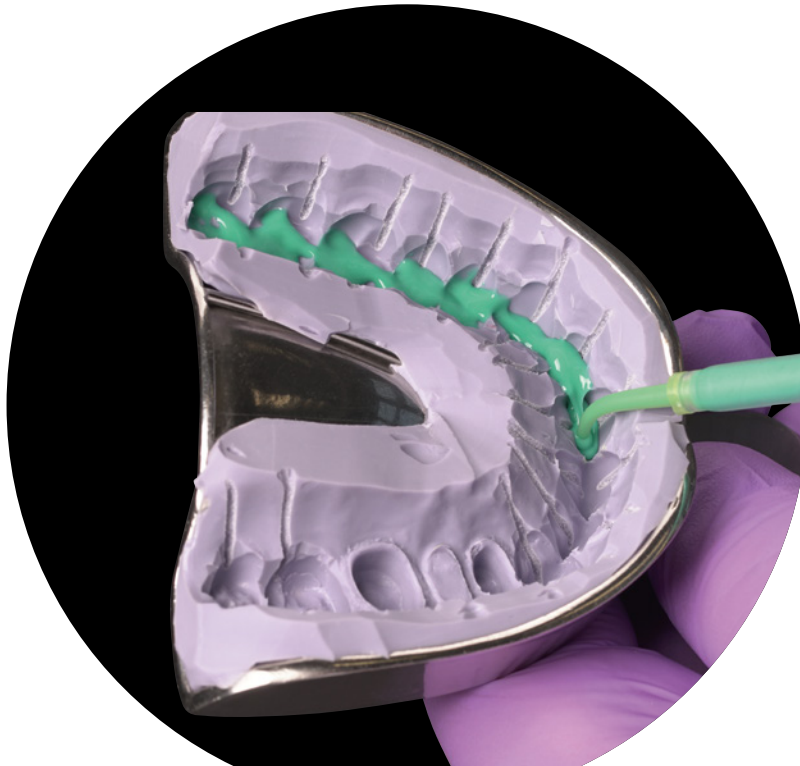


Fig. 75: The intraoral tip also facilitates the access to the lumina during wash material application.

The prepared initial impression is inserted into the mouth and pressure is exerted for the first 3–5 seconds (fig. 76 & 77). Afterwards the impression is kept in place without pressure until final curing. Only as long as the wash material is sufficiently flowable, the tray material is able to adequately recover in the mouth. If the pressure on the impression is exerted for too long, the tray material can be deformed elastically. After removal from the mouth, the material then recovers and leads to too small lumina (results in too small dies). If necessary, the saliva can be removed with a small evacuation tip during setting.



**Tip:** Syringe around the prepared tooth in one go, i.e. always keep the intraoral tip immersed in the impression material to avoid the inclusion of voids.

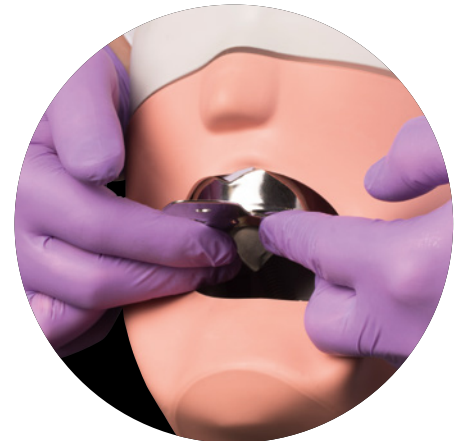
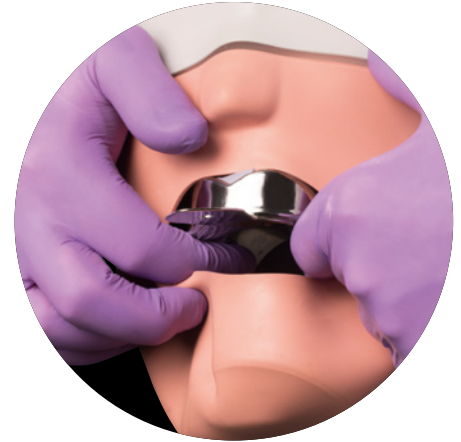
Fig. 76 & 77: Exertion of pressure only in the initial 3–5 seconds, afterwards the impression is kept in place without pressure.

# 20

## Working time and intraoral setting time

The working time starts with mixing of the materials (base & catalyst) and includes filling of the tray, syringing the teeth and inserting the tray into the mouth.

The intraoral setting time starts with the end of the working time. Instructions for use often specify the minimum time in mouth, i.e. the earliest possible point in time to remove the impression from the mouth. However, in practice it needs to be considered that the specified intraoral setting time is measured from the end of the specified working time. In other words, in such cases where the tray is inserted before the end of the specified working time (e.g. single-tooth impression), the intraoral setting time needs to be extended accordingly. Otherwise, the impression material is not yet fully cured at removal. In general, a watch or a material sample at room temperature can help to control the (extraoral) working time.



**Hint:** The intraoral setting time specified in the instructions for use is measured from the end of the specified working time.

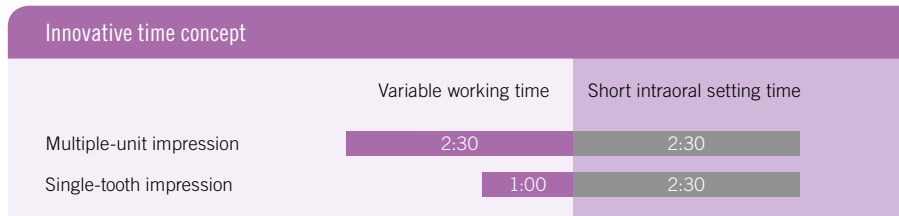


Fig. 78: Variotime combines a variable working time with an always short intraoral setting time.

The A-silicone Variotime offers an intelligent time-concept. Due to its special formula, Variotime controls the polymerization kinetics by mouth temperature. In other words, Variotime combines a variable working time varying from 1:00 to 2:30min with an always short intraoral setting time of 2:30min (fig. 78). Thus, more leeway is given and the necessity for an extension of the time in mouth is reduced.

# 21

## Removal of the impression

After the setting of the impression material, the impression is removed from the mouth. For the removal the index finger is placed vestibularly on the rim of the tray on each side and pressure is exerted slowly (fig. 79). The thumbs are located underneath the tray between upper and lower jaw in order to protect the teeth of the opposing jaw in case the tray suddenly releases (fig. 80).

If possible, the impression is removed in the axial direction of the prepared tooth/teeth, so that the impression in the area of the prepared teeth experiences the least deformation. As the posterior teeth in the upper jaw are inclined to the buccal, the impression should be first released on the side with the unprepared teeth. In the lower jaw where the teeth are inclined to the lingual, the impression is first released on the side with the prepared teeth. Concerning the front teeth: the impression is first released from the dorsal vestibulum and then tilted towards the front teeth, enabling a tray removal parallel to the axes of the prepared teeth.



**Hint:** If strong undercuts of the jaw impede a quick release of the tray, do not simply pull at the tray handle. Instead, alternately exert pressure with the index fingers on the vestibular impression tray rim until the impression releases (fig. 81).

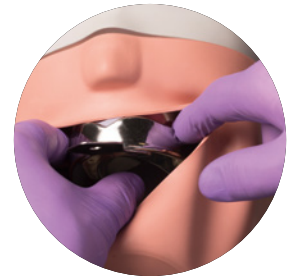
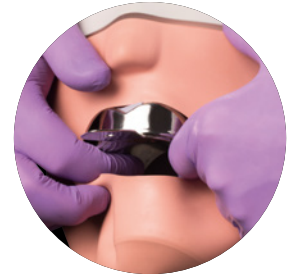
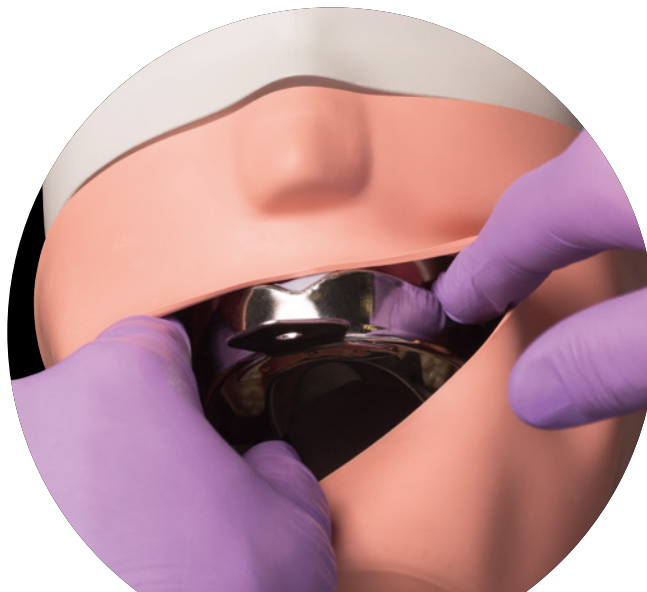Fig. 79 & 80: Release of the impression tray from vestibular. The thumb serves as protection for the teeth of the opposing jaw.

Fig. 81: Do not simply pull at the tray handle, but alternately exert pressure on the tray rim from vestibular until the impression releases.

# 22

## Assessment of the impression

Afterwards, the impression is rinsed under running water (fig. 82), dried and critically assessed. The wash material should completely cover all areas of the initial impression as a very thin and uniform layer (fig. 83). Incomplete or too thick layers of wash material can induce fitting irregularities in the restoration.

A possible reason for an uneven layer of the wash material is the uneven exertion of pressure during insertion. Entrapped air voids in the wash material or a thin hollow lying membrane of wash material (tiny “ramifications” can be seen) can occur when the initial pressure is briefly interrupted and then resumed again, thus inducing a negative pressure between initial impression and wash material.

Possible reasons for a too thick layer of wash material are: Application of too much wash material. Too little and too short initial pressure. Missing or incorrectly cut escape channels. Exceeding of the working time, so that the wash material was already slightly cured during the insertion of the tray.

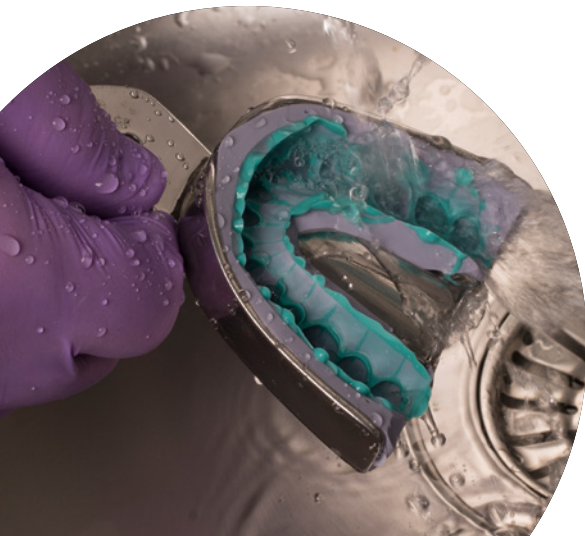


Fig. 82: Cleaning of the impression under running water.

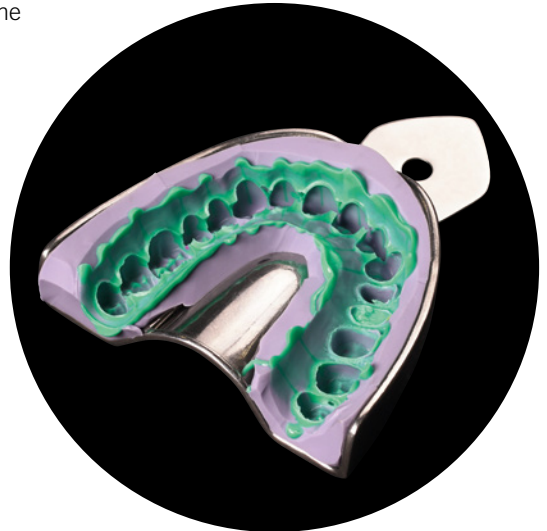


Fig. 83: Finished Two-step impression (Variotime Heavy Tray & Variotime Extra Light Flow).



# 23

## Cleaning and disinfecting the impression

Immediately after the removal from the mouth, the impression is thoroughly rinsed under running water. Prior to the transfer to the lab, the impression has to be disinfected by using specifically suitable disinfectants. Other disinfectants, such as surface disinfectants, can not only damage the impression material but also the model plaster. In addition, it needs to be ensured that the disinfectant is suitable for the used class of impression material.

To ensure that all areas of the impression are reached during immersion disinfection, a complete wetting of the impression is necessary. The exposure time specified in the instructions for use has to be strictly followed. Once the exposure time has elapsed, the impression is thoroughly rinsed under running water and dried afterwards. Ideally, the number of impressions that is disinfected in the immersion bath is recorded to ensure a timely exchange of the solution and thus the efficacy of the disinfection solution.

The information about impression disinfection in the dental practice should be given to the dental lab. Otherwise, the lab has to assume that the impression is not disinfected and needs to take appropriate measures.



**Tip:** Air bubbles at the impression, that impair the complete wetting, can be avoided by repeatedly dipping the impression briefly into the disinfection solution.



**Hint:** The disinfection solution needs to be rinsed off thoroughly, as residues of the disinfection solution can damage the model plaster.

# 24

## Storage and transport of the impression

A-silicone impressions have no special requirements concerning storage and transport, as addition curing silicones possess a high dimensional stability. However, for best results the following hints for storage and transport should be considered:

Ideally, only the tray touches the transport box. Special transport containers allow a suspended fixation of the impression trays. Otherwise, the transport box needs to be upholstered to avoid damage of the impression due to sliding around.

Dry conditions should be ensured during storage and transport of silicone impressions. Temperatures above 25°C are to be avoided as high temperatures can cause irreversible volume changes of the impression material.

# 25

## Opposing arch impression, bite registration and provisional

In addition to the precision impression, an impression of the opposing jaw and a bite registration are necessary for the fabrication of the indirect restoration. Usually alginate or alginate substitute impression materials are sufficient for the situation impression of the opposing jaw. For the bite registration (fig. 84) specially suitable A-silicones with an extra-high final hardness are available.

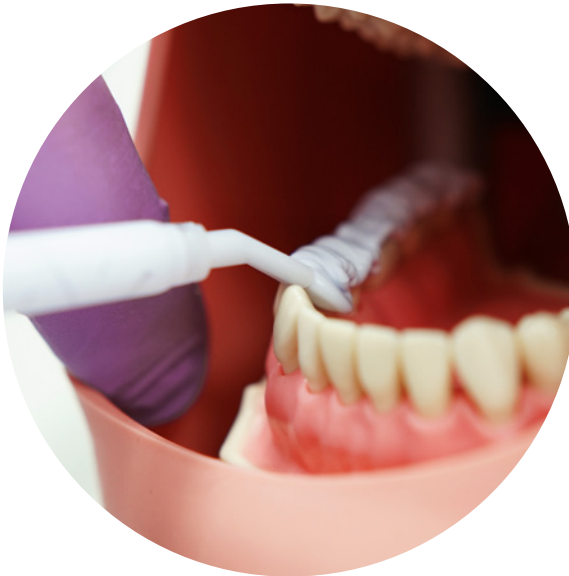

Fig. 84: Application of Variotime Bite with a specially suited wide tip (bite registration tip).



For further information on Variotime and its application visit:  
[kulzer.com/variotime](http://kulzer.com/variotime)

