

Publications

Study

Case Report

Klaus Louis Gerlach, Dominik Niehues
Clinic for Oral and Maxillofacial Surgery
Otto-von-Guericke-University, Magdeburg, Germany

**Treatment of jaw cysts with
a new kind of nanoparticular
hydroxyapatite**

Scientific Information
Ostim®

Objective

Aim of this study was to show the treatment of maxillofacial bone defects with the bone grafting material Ostim.

Material and Methods

40 patients with ages ranging between 15 and 80 years were treated with the nanoparticulate, phase-pure hydroxyapatite Ostim in the following indications: odontogenic cysts and odontogenic keratocysts (33 cases, after com-

plete cystectomy), impacted and ectopic teeth (8 cases) and apicoectomies (3 cases). On average 3.2 ml of Ostim were used. Wounds were closed saliva-tight. X-ray controls were performed after 3-5, 6 resp. 12 months.

Results

44 cases of maxillofacial bone defects

Indications	<ul style="list-style-type: none"> - 33 Jaw cysts - 8 Defects following surgical tooth removal - 3 Apicoectomies <p>Mean length of defects: 6-89 mm Mean height of defects: 3-30 mm</p>
Osseous regeneration	<p>Defects < 3cm: after 3 months Defects > 3cm: after 6-12 months</p> <p>Entire osseous regeneration was observed at the latest 12 months after surgery in all cases.</p>
Tolerability	No serious complications were observed; occasionally occurring secondary haemorrhage or wound dehiscence were successfully treated.

Case Study

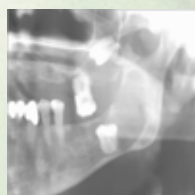


Fig. 1
Follicular cyst originating from ectopic tooth 38. There is another cyst originating from tooth 28 in the region of the left maxillary sinus.

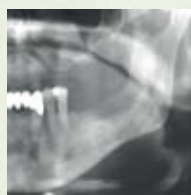

Fig. 2
Extensive bone regeneration of the cyst cavity is visible in the 3-month postoperative radiological check.

Conclusions

The x-ray control showed a complete osseous integration in defects up to 3 cm after 3 months, in more voluminous defects after 6 months and in particular cases within 12 months.

Due to the good clinical results with mainly uncomplicated healing, effective resorption and obvious bone regeneration, the use of Ostim can be recommended for the treatment of bone defects

originating from jaw cysts and surgical tooth removal.

Source: Mund Kiefer GesichtsChir [2007] 11:131-137

Contact in Germany

Heraeus Kulzer GmbH
Grüner Weg 11
63450 Hanau
Phone +49 (0) 6181 355 444
Fax +49 (0) 6181 353 461
info.dent@heraeus.com
www.heraeus-kulzer.de

Contact in the United Kingdom

Heraeus Kulzer Ltd.
Heraeus House, Albert Road
Northbrook Street, Newbury
Berkshire, RG14 1DL
Phone +44 (0) 1635 30500
Fax +44 (0) 1635 30606
Mail: sales@kulzer.uk
www.heraeus-kulzer.com

Contact in Australia

Heraeus Kulzer Australia Pty. Ltd.
Locked Bag 750
Roseville NSW 2069
Phone +61 29 417 8411
Fax +61 29 417 5093
Mail: sales@kulzer.com.au
www.kulzer.com.au